

Non-Traumatic Rupture of the Spleen in a Case

Kapoli Wetshi Alphonse, Kapoli Mateleka Marco, Madiela Maluinda Daddy, EbalantshimJp and KapoliIsheleka Jean-Marie

Human Sciences Research Center (CRESH), Ophthalmology And Development Research Center (CROD), National Pedagogical University (UPN) And University Of Kindu (UNIKI).

Department of History and Social Sciences, Health and Development Section.

ARTICLE INFO

Article history:

Received: 13 October 2020;

Received in revised form:

1 May 2021;

Accepted: 14 May 2021;

Keywords

Spleen,
Abdominal ultrasound.

ABSTRACT

We report the case of a 49-year-old patient admitted to our emergency department at the Kintambo Reference General Hospital for spontaneous rupture of the spleen. At the admission of the patient, we found a pallor of the conjunctiva, the abdomen was distended, slightly contracted with splenomegaly on palpation. The biological assessment was normal. Abdominal ultrasound showed splenomegaly of homogeneous echostructure and peritoneal effusion in the form of a dense hypoechoic plaque. Abdominal CT revealed heterogeneous splenomegaly complicated by spontaneous rupture of the spleen with capsular hematoma and peritoneal effusion of average abundance. Splenectomy was recommended in our patient.

© 2021 Elixir All rights reserved.

Introduction

Non-traumatic or spontaneous ruptures of the spleen are rare but potentially life-threatening [6]. The mortality of this condition is mainly related to delay in diagnosis and treatment, as well as to risks related to the terrain and the severity of the underlying pathology [7,8]. It requires in most cases a splenectomy. They can occur either on a healthy macroscopic spleen, or access to malaria or on a pathological, for example tumoral, spleen.

In our study, we report the case of a 43-year-old patient, with no particular antecedents, followed in our emergency department of the Kintambo General Referral Hospital, for a non-traumatic rupture of the spleen.

Patient and Method

This is a 49-year-old patient with no particular antecedents addressed to the Kintambo General Referral Hospital's emergencies for sudden onset acute abdominal pain. At admission the patient was conscious, oriented, hemodynamically stable, the blood pressure was 120 / 60mmHg, with a heart rate of 80 beats per minute, the patient's conjunctiva were pale, the abdomen was distended, slightly contracted with splenomegaly on palpation. The biological assessment was normal. Abdominal ultrasound showed a homogeneous echogenic splenomegaly and a peritoneal effusion in the form of a dense hypoechoic pad. Abdominal CT evoked heterogeneous splenomegaly complicated by spontaneous rupture of the spleen with sub-capsular hematoma and peritoneal effusion of average abundance.

A splenectomy was recommended in our patient.

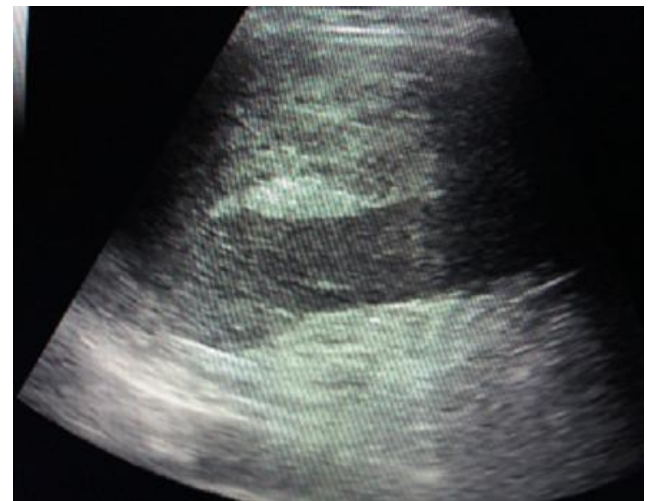


Figure 1. Ultrasound showing an echoic range of the splenic lodge

Discussion

Non-traumatic ruptures of the spleen are twice as frequent in men. The age varies from 2 to 81 years (mean = 42 years). In about a third of cases there are signs of shock at the first examination. In 8% of cases, patients die before being operated on and the diagnosis is made only at the autopsy. In 85% of cases, patients are treated with splenectomy. In 7% of patients (especially in the context of infectious mononucleosis) conservative medical treatment without surgery was attempted [3].

The causes of non-traumatic rupture of the spleen [1] are dominated by infectious and haematological diseases, which represent more than half of the cases. Infectious causes (30%) are generally represented by infective mononucleosis and

malaria, while hematologic causes (27%) are mainly represented by hematological malignancies. Other causes are much rarer: solid or benign tumors of the spleen (11%), digestive pathologies (pancreatitis, portal hypertension) (10%), rheumatological causes (4%) and renal insufficiency at the stage of dialysis (3%). In almost 5% of cases, no etiology and no notion of trauma are found as the case of our observation [1].

Non-traumatic ruptures of the spleen are often revealed by a surgical emergency board. It may be an acute form with hypovolemic shock, or subacute shock in the form of predominantly left-sided diffuse abdominal pain associated with hypotension and anemia [2,3]. The existence of abdominal pain and painful massive splenomegaly, leading to splenic involvement that must be urgently confirmed by ultrasound, which is the first-line examination. However, the CT scan has a better sensitivity to assess the lesions [4].

Therapeutically, splenectomy is the radical treatment of spontaneous ruptures of the spleen. Nevertheless, the morbidity of splenectomy, the improvement of surgical techniques and intensive care and the role of the spleen in the immune response allow us to propose a conservative treatment. This seems to be an alternative subject to certain conditions: hemodynamic stability, use of transfusion of less than 2 red blood cells, regular daily clinical and biological monitoring, rest and hospitalization in a department close to a surgical center [5].

Conclusion

Non-traumatic ruptures of the spleen are rare, potentially life-threatening and difficult to diagnose. The overall mortality is about 20% and seems mainly related to the diagnostic delay and / or the severity of the underlying pathology. The infectious diseases dominated by infectious

mononucleosis (IM) and malaria and haematological diseases, dominated by haematological malignancies, alone account for more than half of the cases. The diagnosis of certainty is based on abdominal ultrasound. The treatment of choice is splenectomy, conservative treatment is indicated in cases of infectious mononucleosis.

Références

1. Kianmanesh R, Aguirre HI, Enjaumeb F, Valverdec A, Brugièred O, Vacher B, Bleichner G. Ruptures non traumatiques de la rate: trois nouveaux cas et revue de la littérature. *Annales de Chirurgie*. Juin 2003;128(5):303-309.
2. Bauer TW, Haskins GE, Armitage JO. Splenic rupture in patients with hematologic malignancies. *Am Cancer Soc*. 1981 Dec 15;48(12):2729-33.
3. Rhee SJ, Sheena Y, Imber C. Spontaneous rupture of the spleen: a rare but important differential of an acute abdomen. *Am J Emerg Med*. 2008 Jul;26(6):733.e5-6
4. Delgado Millan MA, Deballon PO. Computed tomography, angiography and endoscopic retrograde cholangio pancreatography in the nonoperative management of hepatic and splenic trauma. *World J Surg*. 2001 Nov;25(11):1397-402
5. Papp C, Debord T, Imbert P, Lambotte O, Roué R. Rupture de rate au cours des maladies infectieuses: splénectomie ou traitement conservateur? À propos de troiscas. *Rev Med Interne*. 2002;23:85-91
6. Lippstone M.B, Sekula-Perlman A., Tobin J., Callery R.T., Spontaneous splenic rupture and infectious mononucleosis in a forensic setting. *Del Med J* 1998; 70: 433-437
7. Debnath D., Valerio D., Atraumatic rupture of the spleen in adults. *J R CollSurgEdinb* 2002; 47 : 437-445.