

Recurrent Psoas Hydatid Cyst: Case Report and Literature Review

Othmane Yddoussalah^{1,2}, Mohammed Alae Touzani^{1,2}, Tariq Karmouni^{1,2}, Khalid El Khader^{1,2}, Abdellatif Koutani^{1,2} and Ahmed Ibn Attya Andaloussi^{1,2}

¹Faculty of Medicine and Pharmacy, Mohammed V University, Rabat.

²« B » Urology Department, Ibn Sina Teaching Hospital, Rabat.

ARTICLE INFO

Article history:

Received: 09 October 2017;

Received in revised form:

20 November 2017;

Accepted: 01 December 2017;

Keywords

Hydatid cyst,

Psoas,

Recurrence.

ABSTRACT

Primary retroperitoneal hydatid cysts of the psoas muscle are rare. We report the case of a recurrent hydatid cyst of the psoas muscle in a 57-year-old patient with a left lumbar-iliac mass. Ultrasound and computed tomography contributed to preoperative diagnosis. The mass was completely removed via a retroperitoneal approach. We will discuss in this article the diagnostic and therapeutic aspects of the psoas hydatid cyst.

© 2017 Elixir All rights reserved.

Introduction

Hydatid cyst or hydatidosis is an anthrozoosis caused by human development of the larval form of *Echinococcus granulosus*. The disease is endemic and constitutes a real public health issue in Morocco. Isolated muscle localization is an unusual entity even in endemic countries. It represents less than 3 % of all locations. The psoas remains an exceptional localization. In the literature, only a few clinical cases of the hydatid cyst of the psoas muscle have been described. We report a new observation of a recurrent hydatid cyst located in the psoas muscle.

Patient and observation

Mr A.M, 57-year-old, rural origin, who underwent surgery 20 years ago for a left psoas muscle hydatid cyst, currently hospitalized in the urology department for diffuse pains in the hypochondrium and left flank, associated with paresthesias of the left thigh since 6 months. On clinical examination, he is in good condition, afebrile, with a left lumbotomy scar.

The abdominal ultrasound shows an asymmetry of psoas muscle size, the left is poorly developed and is the site of a heterogeneous formation with a predominant cystic component. The abdominopelvic CT scan confirms the cystic nature of the mass (15 UH), which is retroperitoneal, developed at the expense of the psoas muscle, with the presence of some peripheral calcifications and measuring 64 × 77 mm of major axes (**Figure 1 and 2**). Chest x-rays is normal.

The blood count is normal without hypereosinophilia and the hydatid serology by ELISA and indirect immunofluorescence reaction are negative.

The patient was operated on by an extraperitoneal lomboiliac approach. The surgical field was soaked with oxygenated water, for fear of possible hydatidosis. Exploration revealed a cystic mass at the expense of the psoas muscle. Total perikystectomy was made difficult because of adhesions. The surgical excision piece was made of a proliferative membrane of the hydatid cyst and numerous

daughter vesicles. Microscopic examination of the centrifugation pellet of the hydatid fluid showed scolex and numerous hooks confirming the diagnosis. The postoperative course was simple. Clinical and ultrasound follow-up at 3 and 6 months did not show any local recurrence.

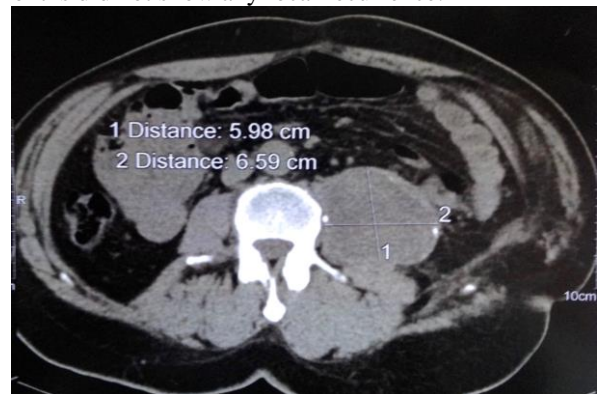


Figure 1. Cross-sectional CT scan without contrast injection, showing a cystic mass developed at the expense of the left psoas muscle.

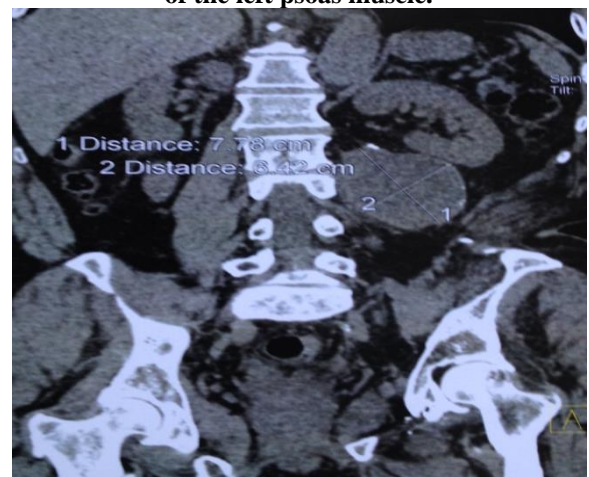


Figure 2. Abdominal CT with coronal sections showing the cyst with its anatomical neighborly relations.

Discussion

Hydatidosis is an anthroponosis due to the *Echinococcus granulosus* larval form. In the adult state, it parasitizes the dog's digestive tract, which is the definitive host. The infestation is done through the consumption of parasitized viscera, especially the liver and lungs of the intermediate host: the sheep. The latter, being the main reservoir of the *Tenia echinococcus*, is contaminated by grazing the contaminated grass by the dog's faeces containing the eggs of the parasite. Man is only an accidental intermediate host. He is infected either directly in contact with the parasitized dog, or indirectly by ingestion of contaminated food. Man is an epidemiological impasse [1]. Hepatic and pulmonary sites account for 90 % of all hydatid cyst locations [2]. This distribution is explained by the blood dissemination of the parasite and the blood flows.

Soft tissue involvement is unusual, described in 0,5 to 4,7 % of cases. It mainly affects the muscles of the neck and lower limbs. This involvement is rare because of the degree of vascularization of the tissues, to the muscular contractions that would prevent the development of the larva and of the lactic acid richness of the muscle which would prevent the growth of the hydatid [3]. Hydatid localization in the psoas muscle is rare. It can be associated in many situations with vertebral localizations of hydatidosis [4].

The diagnosis of psoas hydatid cyst is often difficult. The clinical presentation corresponds to an abdominal mass, of iliac or lumbar localization, fixed to the deep plane. Some cysts may be revealed by complications such as nervous, urinary, vascular compression, or by haematogenous superinfection, which can lead to sepsis [2]. Differential diagnosis is made with all cystic or mixed retroperitoneal tumors, pyogenic abscesses or tuberculous abscesses [5]. In our situation, the notion of a hydatid cyst of the psoas muscle in the antecedents led to the diagnosis of recurrence. Imaging is essential for diagnosis and pre-therapeutic assessment [6]. Ultrasound is a first-line non-invasive examination with an estimated diagnostic reliability of 96 % [7].

The ultrasound aspect reproduces the stages of the Gharbi's classification and reflects the evolutionary stage of the disease, in the deep localizations like psoas a CT scan remains necessary. Computed tomography allows easy diagnosis with a more accurate topographic assessment [8]. The morphological aspects are identical to those described in ultrasound. Magnetic resonance imaging is an expensive examination for benign pathology. It has a diagnostic contribution in the case where the cysts are not characteristic in ultrasound or in scanning especially in the pseudo-tumor forms. It allows an axial, frontal, sagittal and oblique multiplanar study and allows a detailed study of the wall and cystic contents [9].

Regarding hydatid serology, in addition to its role in diagnostic confirmation, it allows to follow the post-therapeutic evolution of the hydatid cyst, to formulate a prognosis and to detect a secondary hydatidosis early. Thus, any elevation in the six-month period following the intervention is synonymous with recurrences or other hydatid localizations. Qualitative and quantitative methods are difficult to interpret, however Western Blot is more sensitive and specific [10]. The only curative treatment of the hydatid cyst is complete surgical excision and irrigation of the surrounding tissues with a hypertonic scoliced solution.

World Health Organization guidelines suggest several specific approaches for classical hydatidosis, but there is no mention of unusual localizations [11].

For psoas cysts, the extraperitoneal approach is the best way to minimize the risk of hydatid dissemination, secondary suppurations and postoperative occlusions [2,12]. The excision of these cysts must be done without sacrificing any organ, but it is sometimes impossible because of intimate contact with neighboring structures (crural nerve and lumbar veins) [13]. In this situation, pericystectomy appears to be the best approach due to its non-invasive nature and its efficiency [14].

The risk of recurrence of the hydatid cyst remains among the main long-term complications of this pathology. The rate in the literature with an average follow-up of 16 months is estimated at 4,3 % [15]. The preventive measures are: one-time surgical resection, meticulous protection of the surgical field, and post-operative administration of mebendazole [15].

Conclusion

The hydatid cyst of the psoas is rare and must be evoked before any lumbar or iliac cystic mass, especially in hydatid endemic countries. The respect of the surgical rules and an extraperitoneal approach will make it possible to avoid, in the majority of the cases, a local recurrence. But the best treatment is essentially based on the prophylaxis of hydatidosis.

Competing interests

The authors declare no competing interest.

Acknowledgements

We would like to thank the Ibn Sina Hospital Department of Pathology for their friendliness and availability.

Author contributions

All authors contributed in the development of this publication and approved the final manuscript.

Références

- [1] Mseddi, M., Mtaoumi, M., Dahmene, J., Ben, H. R., Siala, A., Moula, T., & Ben, A. M. (2005). Hydatid cysts in muscles: eleven cases. *Revue de chirurgie orthopedique et reparatrice de l'appareil moteur*, 91(3), 267-271.
- [2] El Malki, H. O., El Mejdoubi, Y., Bouslami, B., Mohsine, R., Ifrine, L., & Belkouchi, A. (2007). Kyste hydatique du muscle psoas. *Cahiers d'études et de recherches francophones/Santé*, 17(3), 177-179.
- [3] Soufi, M., Lahlou, M. K., Messrouri, R., Benamr, S., Essadel, A., Mdaghri, J., ... & Chad, B. (2010). Kyste hydatique du psoas: à propos de deux cas: Hydatid cyst of the psoas: a report of two cases. *Journal de Radiologie*, 91(12), 1292-1294.
- [4] Tekkök, I. H., & Benli, K. (1993). Primary spinal extradural hydatid disease: report of a case with magnetic resonance characteristics and pathological correlation. *Neurosurgery*, 33(2), 320-323.
- [5] Angulo, J. C., Granell, J., Muguera, J., & Sanchez-chapado, M. (1999). Primary bilateral hydatidosis of the psoas muscle. *The Journal of urology*, 161(5), 1557-1558.
- [6] Kehila, M., Allegue, M., Abdessalem, M., Letaief, R., Said, R., Khalfallah, A., ... & Jerbi, A. (1987). Le kyste hydatique du muscle psoas. A propos d'un cas. *Journal de radiologie*, 68(4), 265-268.
- [7] Hammami, T., Noomane, F., Ketata, M., Ganneme, Y., Nasr, M., Zouari, K., & Hamdi, A. (2002). Kyste hydatique musculaire de la cuisse. À propos de trois observations. *Revue de chirurgie orthopedique et reparatrice de l'appareil moteur*, 88(2), 193-196.
- [8] Von Sinner, W. N., & Stridbeck, H. (1992). Hydatid disease of the spleen: ultrasonography, CT and MR imaging. *Acta Radiologica*, 33(5), 459-461.

- [9] M'Rad, S. B., Mathlouthi, A., Merai, S., Ghrairi, H., Mestiri, I., M'Rad, K. B. M., & Djenayah, F. (1998). Hydatidose multiple de la cuisse: Place de l'imagerie par résonance magnétique. *J radiol*, 79, 877-879.
- [10] Makni, F., Hachicha, L., Mseddi, F., Hammami, H., Cheikhrouhou, F., Sellami, H., ... & Beyrouiti, I. (2007). Parasitologie. *Bull Soc Pathol Exot*, 100(3), 171-173.
- [11] Gemmell, M. A., Meslin, F. X., & Pawlowski, Z. S. (2001). WHO-OIE Manual on Echinococcosis in Humans and Animals: A Public Health Problem of Global Concern.
- [12] Melis, M., Marongiu, L., Scintu, F., Pisano, M., Capra, F., Zorcolo, L., & Casula, G. (2002). Primary hydatid cysts of psoas muscle. *ANZ journal of surgery*, 72(6), 443-445.
- [13] Balik, A. A., Çelebi, F., Başoğlu, M., Ören, D., Yildirgan, I., & Atamanalp, S. S. (2001). Intra-abdominal extrahepatic echinococcosis. *Surgery today*, 31(10), 881-884.
- [14] Yüksel, B. C., Akbulut, S., & Hengirmen, S. (2008). A minimally invasive treatment option in primary muscular hydatid cyst: report of 2 cases. *Canadian Journal of Surgery*, 51(2), 153.
- [15] La Greca, G., Pulvirenti, E., Gagliardo, S., Sofia, M., & Russello, D. (2011). Muscle-Sparing Approach for Recurrent Hydatidosis of the Thigh and Psoas: Report of a Rare Case. *PLoS neglected tropical diseases*, 5(1), e840.